

ENDODONTIC TREATMENT OF MANDIBULAR CENTRAL INCISOR WITH TWO CANALS

1Poshali Goyal, 2Sunil Malhan, 3Gursandeep Kaur Sandhu, 4Shweta, 5Himani Kapila

1Post Graduate Student, Department of Conservative Dentistry and Endodontics

Desh Bhagat Dental College, Mandi Gobindgarh, Punjab

2Professor and Head of Department of Conservative Dentistry and Endodontics

Desh Bhagat Dental College, Mandi Gobindgarh, Punjab

3Professor, Department of Conservative Dentistry and Endodontics

Desh Bhagat Dental College, Mandi Gobindgarh, Punjab

4Post Graduate Student, Department of Conservative Dentistry and Endodontics

Desh Bhagat Dental College, Mandi Gobindgarh, Punjab

5Lecturer, Desh Bhagat Dental College, Mandi Gobindgarh, Punjab

Corresponding author: PoshaliGoyal,

Post Graduate Student, Department of Conservative Dentistry and Endodontics Desh Bhagat Dental College, Mandi Gobindgarh, Punjab,

Email id: poshaligdb@gmail.com, Contact No. 8360562463

Abstract

Anatomy of root canal of mandibular incisors present with various type of different variations. The prevalence of presence of two canals with different apical foramina has been found to be 0.3% to 10%. Many studies have shown that 11%-40% of mandibular incisors possess two canals. The important aspect of understanding the root canal morphology is considered to be a successful endodontic treatment. This case report is done to evaluate the discovery and successful management of complex canal anatomy in mandibular incisors.

Keywords: mandibular, incisors, apical foramina, root canal morphology.

Introduction

Inadequate understanding and knowledge of the anatomical variations in root canals is the primary cause of endodontic failure. Because of the lack of the dentist knowledge and understanding of root canal morphology or lacks the experience and ability to navigate the canal, they frequently fail to notice the presence of additional canal and leave it untreated. Before beginning endodontic treatment, the dentist must be well-versed and should have proper understanding in root canal morphology¹. For good prognosis after root canal treatment, the whole canal system framework must be thoroughly cleaned, debrided, and filled and clinicians must be aware about the different root canal designs².

Vertucci in 1974 classified the different canal configuration of mandibular incisors into four types:

Type I: Single canal is present from the pulp chamber to the apex.

Type II: Two separate canal leaves the pulp chamber, but join short of the apex to form one canal.

Type III: One canal leaves the pulp chamber, but it divides into two within the body of the root, the canals merge again to exist as one canal.

Type IV: Two separate and distinct canals are present from the pulp chamber to apex³.

Endodontic treatment of single rooted teeth is simple because these teeth usually have single root canal. The morphology of mandibular central and lateral incisors is very similar to each other and Many studies have examined the root canal systems of these single rooted teeth, which shows that it is not as simple as it may appear to be on standard periapical radiographs⁴.

CASE REPORT

46 years old Male patient reported in the Department of Conservative Dentistry and Endodontics, Desh Bhagat Dental College and Hospital, Mandi Gobindgarh with a chief complaint of pain and discomfort on biting in the lower left front tooth region since

last 20 days. The nature of pain was moderate, dull aching, and intermittent pain in the lower left front region of teeth. On clinical examination, 31, 32 and 33 were tender on percussion. The patient's medical history was non-significant. The teeth were not mobile and periodontal probing around the teeth was within the normal physiological limits.

After receiving the patient's consent and explaining the current situation to the patient, his clinical evaluation was performed which manifested generalised, severe attrition in mandibular anteriors. The patient was explained about the need for a root canal. Local anesthesia of lidocaine was administered. The access cavity preparation was done with Endo Access Round Diamond Bur (Dentsply/Maillefer, Ballaigues, Switzerland). Firstly the pre operative radiograph was taken and it was found that there are two canals in lower mandibular central incisor and then the buccal canal was located and it was a very constricted canal, lying more towards the buccal wall of the tooth so, the access was later on modified and widened lingually and with Endo Z bur (Dentsply Sirona Pvt Ltd) which revealed the presence of additional lingual canal with the use of DG 16 explorer. And, then it was confirmed radiographically. Lingual modification of conventional access cavities was done to locate extra canal lingual to the main canal.

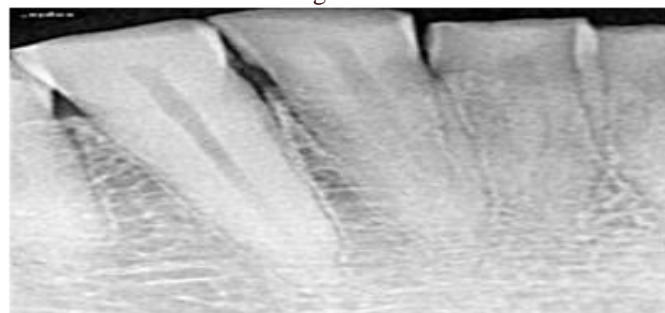


Fig No.1: Preoperative Radiograph

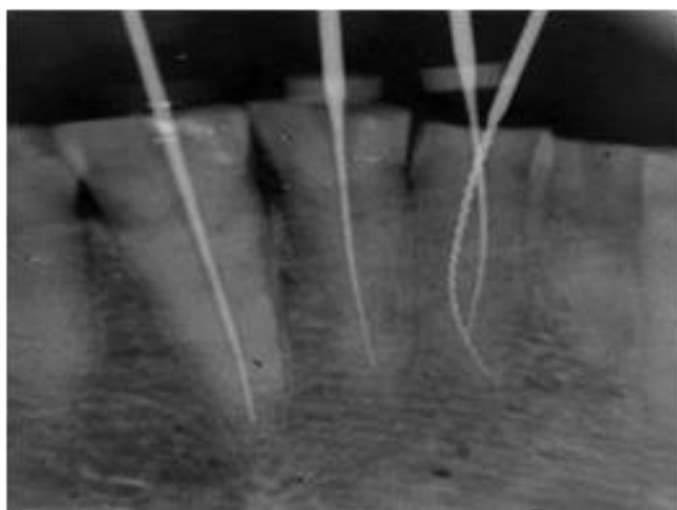


Fig No.2: Working Length radiograph of 31,32,33

Canal patency was achieved with the help of using 10K Files (DentsplyMaillefer, Switzerland) in both the canals, working length was calculated using apex locator (Coltene Canal Pro CL2i Endomotor with Apex Locator) and later verified by radiographs.

Working length was calculated by placing a 20 no. K file in the buccal canal & 15 no. K file in the lingual canal using digital radiography. The presence of extra canals were verified using different angulations while taking radiographs. The canal shaping was done with Neoendo flex rotary files (Orikam Healthcare, India) in the sequence of #17(4%), #20(4%) and #25(4%) buccal canal and till #20(4%) in lingual canal. The irrigation solution included 17% EDTA and 2.5% sodium hypochlorite. After every instrument change, the canals were cleaned with regular saline. The discomfort and tenderness had become reduced by the time the patient was recalled back after five days. The tooth was asymptomatic during the visits and mastercone radiograph was taken.

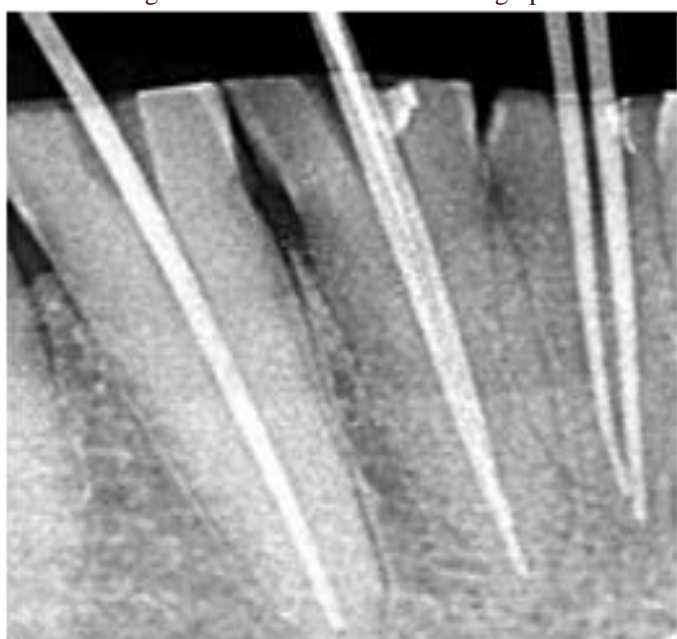


Fig 3. Masterconeradiograph of 31,32and 33

Obturation was performed with #25(4%) guttapercha as master cone in buccal canal and #20(4%) in lingual canal, with Endoseal sealer.

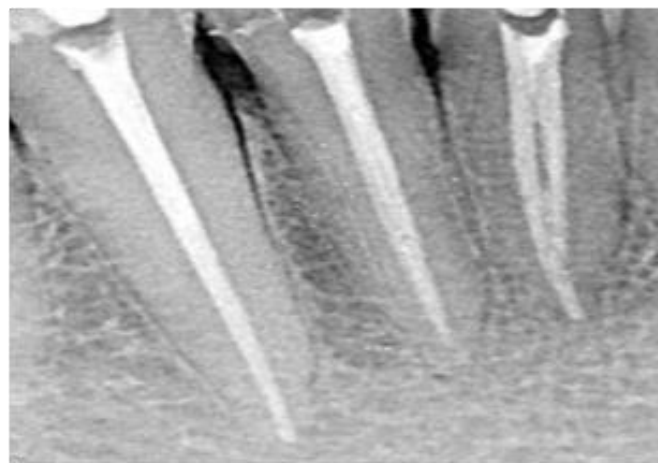


Fig No.4: Obturation radiograph of 31, 32,33

DISCUSSION

Adequate knowledge of anatomic variations is very essential because endodontic success is related to a thorough 3 debridement of the root canal system. Successful and predictable endodontic treatment requires complete knowledge of biology, physiology and root canal anatomy. Teeth with additional roots and/or canals pose a particular challenge 5. The inability to properly locate, identify and effectively treat these additional root canals may lead to treatment failures. A well-designed access preparation is required for a good endodontic result. Without adequate access, instruments and materials become very difficult to handle properly in the highly 1 complex and variable root canal system 1.

When cavities are properly prepared, healthy tooth structure is also preserved, making it possible to directly access apical foramina or, at very least, to easily access the early curve of the canal. Due to their small size and interior structure, lower mandibular incisors may have the hardest access cavities to prepare. Because such teeth have a tendency to frequently contain two canals and are buccolingually orientated and lingual canal is mostly ignored, complete excision of the lingual shoulder is very essential to avoid the chance of missing the canal 6.

To avoid missing this canal, the clinician should extend the access preparation completely well into cingulum gingivally, which, if present, is located directly beneath it. When there are two canals, the buccal canal is the easiest to identify and locate comparatively than the lingual canal and is generally straighter than the lingual canal 7.

Therefore, it is important to thoroughly assess the radiographic features obtained from various angles prior to the beginning of an endodontic treatment 1. Various methods like visualizing the dentinal map and canal bleeding points, using magnification, ultrasonic tips, staining the chamber floor with 1% methylene blue dye, performing champagne bubble test, using DG-16 probe and Cone beam computed tomography (CBCT) imaging 5 are very helpful in the identification of the missed canal 8.

CONCLUSION

The primary reason that endodontic treatment of the mandibular incisor failed was, failure to identify and locate a second canal, usually a lingual canal. This necessitates proper examination of radiographs obtained from all the different perspectives. So it is best to extend the access cavity bucco-lingually & gingivally beneath the cingulum if each mandibular incisor has more than one lingual canal. The careful interpretation of radiographs taken

from different angulations is mandatory. Proper knowledge of modification of access cavity buccolingually and gingivally beneath cingulum and visualizing access preparation under dental operating microscope or dental loupes, will help to detect additional lingual canal if present in each mandibular incisor.

REFERENCES

1. Fouzan KS, Almanee A, Jan J, Al-Rejaje M. Incidence of two canals in extracted mandibular incisor teeth of Saudi Arabian samples. *Saudi Endodontic J.* 2012;2(2):65–9.
2. Hegde V, Kokate S, Shahu Y. An unusual presentation of all the 4 mandibular incisors having 2 root canals in a single patient-a case report. *Endodontol.* 2010;22(2):70–4.
3. Vertucci FJ. Root canal anatomy of the mandibular anterior teeth. *J Am Dent Assoc* 1974;89:369-71.
4. Cantatore G, Berutti E, Castellucci A. Missed anatomy: Frequency and clinical impact. *Endod Top* 2009;15:3-31.
5. S. Cohen and K. Hargreaves, *Pathways of the Pulp*, Elsevier Mosby, 9th edition, 2006.
6. Mattigatti S, Mahaparale RR, Chopade RV, Garg V. Unusual canal morphology in all mandibular incisors in a single patient. *Int J Dent Case Rep.* 2012;2(3):72–6.
7. Herrero-Hernández et. al. Root Canal Morphology of the Permanent Mandibular Incisors by Cone Beam Computed Tomography: A Systematic Review. *Appl Sci* 2020;10;01-15
8. Abella F, Patel S, Duran-Sindreu F, et al. Mandibular first molars with disto-lingual roots: Review and clinical management. *IntEndod J.* 2012;;45::963–78.

