

## RETENTION AND RELAPSE: A REVIEW

<sup>1</sup>Laima zehra, <sup>2</sup>Monita mehta, <sup>3</sup>Chitra, <sup>4</sup>Priyanka Sharma

<sup>1</sup>Post Graduate Student (2nd year), Department of Orthodontics & Dentofacial Orthopaedics,  
Desh Bhagat Dental College & Hospital, Mandi Gobindgarh, Punjab.

<sup>2</sup> Post Graduate Student, (1st year), Department of Orthodontics& Dentofacial Orthopaedics,  
Desh Bhagat Dental College & Hospital, Mandi Gobindgarh, Punjab

<sup>3</sup>Post Graduate Student, (1st year), Department of Orthodontics& Dentofacial Orthopaedics,  
Desh Bhagat Dental College & Hospital, Mandi Gobindgarh, Punjab

<sup>4</sup>Lecturer, Department of Pediatric and Preventive Dentistry,  
Desh Bhagat Dental College & Hospital, Mandi Gobindgarh, Punjab

### Corresponding author:

Laima zehra, Post Graduate Student (2nd year), Department of Orthodontics & Dentofacial Orthopaedics, Desh Bhagat Dental College & Hospital, Mandi Gobindgarh, Punjab. Email id: laimazehra26@gmail.com, Contact No. 7895998325.

### Abstract

Retention and relapse are key concerns in orthodontics, affecting the stability of treatment outcomes. Retainers, both fixed and removable, are used to maintain teeth in their corrected positions. Despite advancements, relapse remains common due to factors like periodontal ligament elasticity and patient compliance. New strategies focus on improving retainer efficacy, enhancing patient adherence, and using adjunctive therapies. Future research aims to develop personalized retention protocols and innovative technologies to prevent relapse, ensuring long-term success in orthodontic treatments.

**Keywords:** Retainers, Retention, occlusion, relapse.

### INTRODUCTION

Retention is the phase of orthodontic treatment, which attempts to keep teeth in the corrected positions after orthodontic (dental) braces. Retention planning starts with appropriate diagnosis, treatment planning, application of correct biomechanics for tooth movement and bringing the teeth in optimal functional occlusion<sup>1</sup>. Without this phase of retention there is a tendency for the teeth to return to their initial position. This unfavorable change from the corrected position is known as relapse.<sup>2</sup>

The retainers can either be removable, so that the patient can take them out to clean, or fixed to the teeth. There is no recognised duration for retention, however reorganization of the collagen fiber bundles in the periodontal ligament occurs over a 3 to 4 month period; at this stage tooth mobility disappears. The gingival fiber network is made up of both collagenous and elastic-like oxytalan fibers. Reorganization of this network occurs more slowly than in the periodontal ligament. The collagenous fibers remodel in 4 to 6 months, whereas the oxytalan fibers may take up to 6 years to remodel. It is believed that the slow remodeling of the supra-alveolar fibers of the gingival complex contribute to the relapse of teeth after orthodontic treatment, especially in those teeth that were initially rotated. The direction of relapse will tend to be toward the original position of the tooth; thus full-time retention for 3 to 4 months following removal of orthodontic appliances is required to allow time for reorganization of the periodontal tissue structures. Retention should be continued part-time for at least 12 months to allow time for reorganization of the gingival fibers.<sup>3</sup>

Retention is the most difficult and challenging stage of orthodontic treatment.<sup>4</sup> Orthodontic forefathers faced the problems of retention and the continued trend, which owes to the biological and mechanical limitations, demands every Orthodontic student to go through the state of art of this perineal problem "Retention and Relapse" which also is the purpose of this library dissertation.

### Historical perspective

In 1934, Oppenheim stated "Retention is one of the most difficult problems in orthodontia; in fact, it is the problem." Kingsley felt that occlusion was the key to stability. The first century Roman writer Pliny & Galen, his countryman in the second century who was the founder of experimental medicine, both recommended filing when a tooth projected from trauma and other reasons. Later in England, Alfred Coleman (1865) wrote about restoration of the former condition by muscular pressure in other words, the first illusion to relapse. In the following year, C.A. Marvin (1866) described the physiologic reasons for retention. Indeed, he went a step further in his writing and emphasized the necessity of the preservation of correct facial expression or "aesthetics" as one of the objectives of orthodontic treatment. Not long after, Brown-Mason (1872) (in England) described a retaining plate for surgically rotated teeth. Jackson (1904) mentioned the importance of retention and designed many retaining devices. Ferrar (1831-1913), also known as one of the fathers of orthodontics-that is, scientific orthodontics - the man who introduced the term "intermittent force". He wrote, according to Weinberger, the greatest text on orthodontia in his experience, said (about retention) that when the teeth are fully regulated they should be retained in position for a year, perhaps longer. A variety of retaining appliance observations and opinions were advocated by the following orthodontic innovators and clinical scholars: Hawley (1919), Hahn (1944), Lundstrom (1929), Hellman (1936), Mershon (1936), Marcus (1938), McCauley (1944), Tweed (1954), and Grieves (1944); experimentally trained research oriented orthodontists, Skogborg (1929) and Oppenheim (1935) and the research-oriented periodontists, Gottlieb (1938) and Orban (1936), who published histologic studies of alveolar tissue and periodontal membranes during tooth movement and retention in animals. George Anderson's (1942) observations led him to the conclusion that nothing was stationary in the human

masticatory field. In contrast, Dallas McCauley (1944) placed great emphasis on maintaining canine position, arch form, and width as related to functional jaw movements to achieve post-treatment stability. Reitan's (1959, 1966, 1967) microscopic studies of postretention treatment changes excited the orthodontic community worldwide. He demonstrated in animal studies that the supracrestal gingival fibers (collagenous) appear histologically taut and directionally deviated after tooth rotation, and that this condition did not lessen even after years of retention. Kole (1959) removed the buccal and lingual cortical plates on human patients before initiating orthodontic movement, somewhat reminiscent of the septotomy of Talbot (1896) and Skogsborg (1927). Edward's (1970) clinical orthodontic study was based on Bauer's (1963) thesis describing mesial and distal incisions of transseptal fibers of rotated teeth in experimental animals and Edward's own similar animal study (1968). Parker (1972), in a clinical study of transseptal fibers, states: Rotational relapse is a normal, predictable, physiological response to abnormal forces. Little (1984) reported on a 10-year postretention relapse study of 450 cumulative cases from the University of Washington group at Seattle, led by Riedel.<sup>5</sup>

#### **Philosophies or schools of thought of retention:**

1. The occlusion school: Kingsley (1880) stated, "The occlusion of the teeth is the most potent factor in determining the stability in a new position". Many early writers considered that proper occlusion was of primary importance in retention. The importance of a functional and stable occlusion is important to maintain retention.
2. The apical base school: In the middle 1920s, a second school of thought formed secondary to the writings of Axel Lundstrom, who suggested that the apical base was one of the most important factors in the correction of malocclusion and maintenance of a correct occlusion.
3. The mandibular incisor school: Grieve and Tweed suggested that the mandibular incisors must be placed and kept upright and over basal bone. Lower incisor irregularity after orthodontic treatment may either be due to growth and development, or result from relapse of tooth movements carried out during treatment (Little et al., 1988).
4. The musculature school: Rogers introduced a consideration of the necessity of establishing proper functional muscle balance. Orthodontists have come to realize that retention is not separate from orthodontic treatment but that it is part of treatment itself and must be included in treatment planning.<sup>6</sup>

#### **Theorems of retention**

1. Teeth that have been moved tend to return to their former positions.
2. Elimination of the cause of malocclusion will prevent recurrence.
3. Malocclusion should be overcorrected as a safety factor.
4. Proper occlusion is a potent factor in holding teeth in their corrected positions.
5. Bone and adjacent tissues must be allowed to reorganize around newly positioned teeth.
6. If the lower incisors are placed upright over basal bone, they are more likely to remain in good alignment.
7. Corrections carried out during periods of growth are less likely to relapse.

8. The farther teeth have been moved, the less likelihood of relapse.
9. Arch form, particularly in the mandibular arch, cannot be permanently altered by appliance therapy.
10. Many treated malocclusions require permanent retaining devices.<sup>7</sup>

#### **Types of Retainers**

##### **Removable Retainers:**

The removable retainers provide adequate retention for intra-arch stability and are useful as retainers in patients in where Growth is remaining and are compliant. Various types of removable retainer are:

1. Hawley's retainer and its modification
2. Clip on retainer
3. Wrap around retainer
4. Vander linden retainer
5. Clear retainer

Removable retainers have the advantages of being easier to maintain oral hygiene (as they can be removed for cleaning), and may only need to be worn part-time. It has been shown that in many cases, removable retainers need only be worn at night to maintain dental stability.<sup>8,9,10</sup> Good patient compliance is essential with removable retainers, and if consistent wear is overlooked, relapse occurs. This method of retention places full responsibility directly on the patient in maintaining tooth alignment following orthodontic treatment.

The most common examples of removable retainers used worldwide are the Hawley-type retainers (with an acrylic baseplate and usually a wire labial bow, Figure 1) and thermoplastic retainers (made from clear plastic, Figure 2). There is some evidence to suggest that, at least in the short-term, patients prefer the appearance and comfort of thermoplastic retainers which are more cost-effective and slightly more effective in maintaining stability, particularly in the lower arch.<sup>11,12</sup> There is no high quality, long-term research to indicate whether these advantages are maintained long-term.

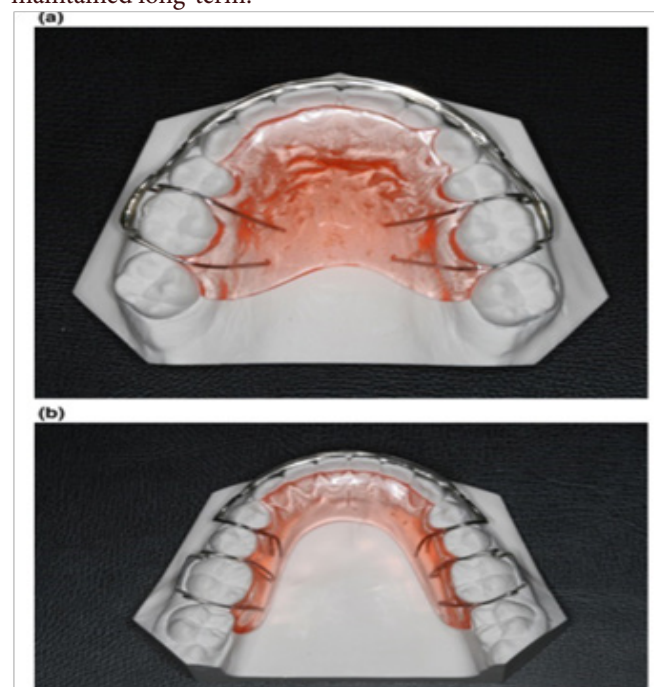


Fig No.1: (a) Upper Hawley style removable retainer. (b) Lower Hawley style removable retainer.

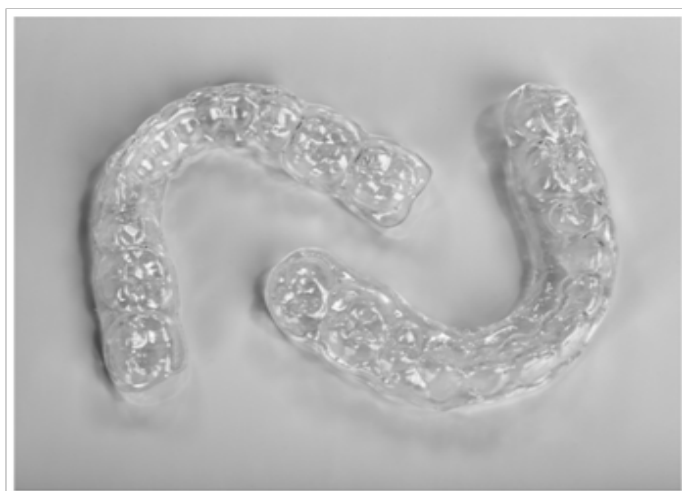


Fig No 2: Upper and lower clear thermoplastic removable retainers.

### Hawley's retainer

The most common removable retainer is the Hawley retainer, designed in the 1920's by E H Hawley. It incorporates clasps on molar teeth and has a characteristic outer bow with adjustment loops, from canine to canine. There is an acrylic coverage of the palate, which automatically provides a potential bite plane effect to retain overbite correction and rigid enough to maintain palatal expansion achieved during Orthodontic treatment. 13

Hawley retainer can be modified according to the clinical requirement for retention. The selection of clasp design is important as clasp crossing the occlusal table can disrupt the corrected tooth relationships. Some modifications are listed in Table 1.14

**Table 1: Modifications of Hawley retainers**

Modification	Uses
Hawley with anterior bite plane	Anterior bite plane can be fabricated in its palatal portion to control bite depth, in corrected deep bite cases.
Hawley with bow soldered to buccal section of Adams clasp	In tight contacts, there can be wedging effect due to crossover wire. To overcome this, labial bow can be soldered to the bridge of Adams clasp which helps to maintain the closed extraction site.
Hawley with long labial bow	The drawback of space opening between canine and premolar, with standard Hawley retainer can be prevented with the use of labial bow extending from first premolar of one side to another side.
Hawley with C-clasp on second molars distally	When there is chance of occlusal interference over posterior occlusion, c-clasp with distally approaching ring on second molars, can be fabricated.

Hawley with fitted labial bow	Fitted labial bow anteriorly and the base plate posteriorly is used for better incisors control.
Hawley with finger/Z-spring	The incorporation of finger/Z-springs makes it active appliance used to achieve tipping movement.

### Recent Advances

#### 1) Clear bow: (Hawley with clear outer bow)

The Clearbow is an aesthetic component that may be used in the fabrication of retainers or other removable orthodontic appliances. It comprises a clear strap made of food-grade polyethylene terephthalate (PET) and grade 316 stainless steel, joined together at a CoiltightJoint. 15

The bow is 2.75-mm wide and possesses a concave inner surface structure to provide optimum tooth contact and thereby superior retention. 15

#### 2) Astics Translucent Labial Bow (ATLB)

The Astics bow is semi-solid, manufactured of fiber-reinforced composite resin, fitting into a tube welded to the Adams clasps. Adams clasps wrap around the first permanent molars to provide retention. There are metallic connectors and also an acrylic base plate. Contrary to the Hawley, the Adams clasps are welded to metallic connectors, and they also support the Astics bow. The wire assumes its final shape on the working model, light-cured in contact with labial dental surfaces.16

#### 3) Reinforced Removable Retainer (RRR)

The RRR is a modification of the well-known Hawley appliance, being reinforced with metallic mesh and also has ball clasps. The mesh adds resistance to breakage without adversely affecting soft tissue health, since it is fully integrated into the body of the acrylic. The mesh is kept extremely thin to facilitate handling during manufacturing, and to prevent the appliance thickening and becoming uncomfortable and unacceptable. Additionally, ball clasps increase retention and stability.16

#### 4) Hawley retainer with C-clasps

Settling cannot occur where wires cross the occlusion, and iatrogenic problems may arise in these areas. There is often sufficient clearance for a crossover wire between the canine and premolar, however, and the posterior wire can be fabricated as a distally approaching ring or C-clasp rather than an Adams clasp to avoid occlusal Interference.

### Clip on retainer

A second major type of removable retainer is a clip-on retainer (C3-3 clip or 4-4 clip). It consists of acrylic bar (usually wire reinforced) along the labial and lingual surfaces of the teeth. This retainer though quite esthetic is often less comfortable than a Hawley retainer. It is used to control alignment of anterior teeth or preferred in mandibular arch when mandibular teeth were well aligned and prior to treatment, retention of these teeth is unnecessary and undercuts lingual to molars make it difficult to extend retainer posteriorly (Fig.14) It is generally used in cases with anterior spacing and can also be used to realign mandibular incisor if mild crowding develop after the treatment.13

### Begg's modified wraparound retainer

Original Wraparound retainer was popularized by P.R. Begg. It



consists of labial wire that extended till the last erupted molar and curves around it to get embedded in acrylic that spans the palate. There was no cross-over of wires between the canine and second premolar there by eliminating the risk of extraction space opening up. The original design was modified by placing a single arrowhead in distal undercut of last tooth both first and second molar can be incorporated in the retainer to improve retention of the appliance.<sup>17</sup>

**Screw-Type Wrap-Around Retainer:** Begg's wrap-around retainers are the most commonly used retainers after orthodontic correction for providing stability to the achieved orthodontic correction. It is not always possible for the patient to visit the Orthodontist periodically, especially during situations like pandemics. This new design of Begg's retainer has been modified with the addition of expansion screws for self-activation, thus reducing the need for the patient to visit the Orthodontist for activation of the retainer.<sup>18</sup>

#### **Vander linden retainer**

The Vander linden retainer is constructed to offer complete control over the maxillary anterior teeth, with firm fixation provided by clasps on the canines. The continuous 0.028"labial arch and left and right three quarter 0.032"molar clasps are embedded in the palatal acrylic plate. The premolars and molars should be of acrylic, except where there are clasps. This retainer does not usually interfere with the occlusion, because most maxillary lateral incisors have rounded disto-incisal corners with sufficient space for the retainer wire on the palatal side. Nevertheless the patient's occlusion should be checked to ensure that 0.028" wire can pass between the lateral incisor and canine without causing interference.<sup>19</sup>

#### **Clear retainer/invisible retainer**

are also a type of removable retainer made with varying thickness of preformed thermoplastic sheets. They are considered as invisible retainer that can be made by Biostar or Vacuum pressure machines using thermoform sheets. (Essix retainer, thermoplastic retainer, or vacuum formed retainer) were the first thermoplastic clear retainers introduced in 1993 by **Dr. John Sheridan**.

As these retainers are made entirely of transparent plastic, which makes them less noticeable and more esthetic than the traditional wire retainers, they are easily accepted by the patients.

These retainers also acts as positioners and gently guide the teeth into proper position and can correct tooth discrepancies. They can serve as temporary bridge for missing anterior teeth. They also act as a night guard for subjects who have the habit of Bruxism and also have a bite plane like effect. The delivery of these retainers require less chair side time. They encourage good dental hygiene as patients can take out their retainer and brush or floss their teeth.

However clear retainer has certain disadvantages like they demand good patient compliance, interferen with settling of occlusion, and can be lost due to its transparency.

There is certain contraindication to use of clear retainers like swollen inter-proximal tissue, Severe pretreatment dental rotations, in cases where arch expansion has been done or inpatient with anterior open bite.<sup>19</sup>

#### **Vacuum-formed retainers (vfrs)**

They were first designed in 1971 by Ponitz and referred in the literature as VFRs, clear overlay retainers (CORs), or Essix retain-

ers. They are invisible retainers made of thermoplastic material like polyethylene polymers and polypropylene polymers. On the one hand, polyethylene polymers are more esthetic, transparent, and allow bonding to acrylic. Hence, they are material of choice when bite planes are to be added in the appliance. Polypropylene polymers, on the other hand, are esthetically inferior and translucent but more durable and flexible compared to polyethylene polymers. The VFRs are fabricated on a vacuum machine that adapts a heat softened plastic by negative pressure and, under vacuum, pulls the thermoplastic material on the working cast. These retainers are made from commercially available materials like Essix C+, Essix ACE, Duran, and Tru-Train. They are also supplied in the market by certain brands like Essix, Zendura, and Vivera. They are available in thicknesses of 0.75, 1, 1.5, and 2 mm. Until now, no uniform standard has been established for the thickness of VFRs. Also, there is no published evidence to indicate whether the differences in thickness influence the effectiveness of VFRs. The most common design for the VFRs is the full coverage including the occlusal surface of the most distal tooth. The VFRs are trimmed past the gingival margin by 1–2 mm on the buccal and 3–4 mm on the lingual side.<sup>20, 21</sup>

#### **Fixed retainers**

Fixed retainers offer the advantage of being in place permanently which removes the need for patient compliance with retainer wear (Figure 3, the retainers are typically bonded to the palatal/lingual surfaces of the labial segments. As they cannot be removed for cleaning, they are more prone to plaque and calculus accumulation.<sup>11</sup> It is therefore vital that patients are provided with clear instructions on oral hygiene measures associated with their bonded retainers. The retainers also need to be checked regularly to ensure that they are still bonded in place. In addition, there are reports of occasional, severe, unwanted tooth movements caused by different types of failed/faulty fixed retainers as a result of the bonding of some or all teeth within the span of the fixed retainer.<sup>22,23,24</sup> This method of retention makes the clinician responsible for the maintenance of the fixed retainer. It is critical during the informed consent process that patients are made aware that if appliance maintenance is not performed by either their orthodontist or general dentist, they are at risk of tooth relapse.

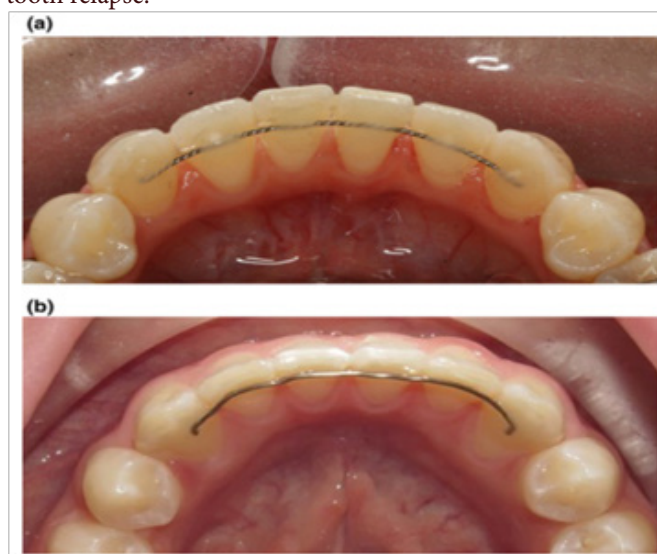

Fig No. 3: (a) Lower fixed retainer; Bonded only at teeth 33 and 43. (b) Lower fixed retainer; Bonded at all the lower incisor teeth.

### **Indications for Fixed Retainers<sup>25,26</sup>**

- Closed midline diastema
- Generalized anterior spacing
- Severe rotations and displaced teeth
- Space closure following mandibular incisor extraction
- Significant incisor proclination during treatment
- Significant increase in lower intercanine width
- Nonsurgically treated open-bite cases
- Impacted teeth
- Teeth with loss of periodontal support
- Teeth with no opposing tooth

### **Instructions and Maintenance of Fixed Retainers**

Fixed bonded retainers should be placed with the utmost isolation and care. They should be checked regularly for any breakage, distortion, or plaque accumulation. They should be replaced when deemed necessary. Failure is common with such retainers owing to improper isolation during placement, distortion of wire during curing, inadequate adhesive or setting time, and direct trauma to the retainer.<sup>27</sup> The site of failure can be at:

- Wire-composite interface (most common)
- Composite-enamel interface
- Stress fracture of the wire<sup>28</sup>

Whenever a fixed retainer is to be repaired, it should be replaced completely without attempting to correct the old retainer. Until the retainers are repaired, the patient is asked to wear the removable retainers.

### **Combination Retainers**

Removable and fixed retainers are used in combination. VFRs are combined with wires which are bonded on the lingual surfaces of teeth. In case the bonded retainer fails, the removable retainer prevents the relapse. Otherwise, if the patient fails to wear the removable retainer, the bonded retainer holds the teeth. The patient does not have to contend with the removable retainers. Also, the doctor avoids confrontations with unreasonable and uncooperative patients and parents.<sup>29</sup> Circumferential supracrestal fibrotomy (CSF) conjoined with a removable retainer has shown to significantly reduce the relapse by 2 mm compared with using a removable retainer alone.<sup>30</sup>

### **Hawlix appliance**

The Hawlix is a removable prosthetic-orthodontic retainer; a fusion of the Hawley and Essix, the latter described by Sheridan and colleagues. The Hawlix was developed to satisfy the aesthetic requirements of adolescent patients who completed orthodontic treatment and required restoration of an absent anterior tooth or teeth. The Hawlix is a hybrid thermoformed and cold-cured retainer that serves dual functions as a prosthetic appliance and an intermediate orthodontic retainer.<sup>31</sup>

The Hawlix is delivered immediately at the end of active orthodontic treatment when fixed appliances are debonded. It is used during the initial retention phase while waiting for the re-organization of the large collagen fibres of the periodontal ligament to stabilise before restorative treatment is provided. In this way, the restorative results are expected to be predictable and not prone to failure due to dento-alveolar and periodontal remodelling. Similar to the hybrid VFR, the Hawlix can also be worn during eating, thus avoiding social embarrassment normally associated with alternative retainers.<sup>31</sup>

### **Adjuncts to retention**

A number of adjuncts have been proposed that aid in retention. These include -:

1. Circumferential Supracrestal Fibrotomy
2. Reproximation
3. Frenectomy
4. Septotomy
5. Corticotomy
6. Immediate torsion

### **Conclusion**

Retention and relapse remain pivotal challenges in orthodontics, demanding a comprehensive understanding and strategic management to ensure lasting treatment success. The use of retainers is fundamental, yet the persistent issue of relapse highlights the need for continual advancements in retainer design, patient education, and adherence strategies. Emerging approaches, including pharmacological interventions and minimally invasive surgical techniques, show promise in mitigating relapse. As research progresses, the focus on personalized retention protocols and innovative predictive technologies will likely enhance our ability to maintain optimal orthodontic outcomes. Ultimately, a multifaceted approach, combining traditional and novel methods, is essential for effective long-term retention and the prevention of relapse in orthodontic care.

### **References**

1. Littlewood SJ, Millett DT, Doubleday B, Bearn DR. Retention procedures for stabilising tooth position after treatment with orthodontic braces. The Cochrane Database of Systematic Reviews (Protocol) ,Issue. 24 May 2000.
2. Allassiry AM. Orthodontic Retainers: A Contemporary Overview. J Contemp Dent Pract 2019; 20(7):857-862.
3. Kharbanda O.P, Darendeliler M.A. Functional Occlusion in Restorative Dentistry and Prosthodontics, 2016.
4. Rev Ed of. Handbook of orthodontics for the student and general practitioner. 3rd ed. Chicago, London, Boca Raton: Year Book Medical Publishers; 1973.
5. Kaplan, H 1988, 'The logic of modern retention procedures', American Journal of Orthodontics and Dentofacial Orthopedics, vol. 93, no. 4, pp. 325-340
6. Graber, Vanarsdall and Vig 2012, Orthodontics Current principles and techniques , Elsevier, Mosby
7. Blake, M & Bibby, B 1998, 'Retention and stability: a review of the literature', American Journal of Orthodontics and Dentofacial Orthopedics. 1988;114(3) 299-306.
8. Gill DS, Naini FB, Jones A, Tredwin CJ. Part-time versus full-time retainer wear following fixed appliance therapy: a randomized prospective controlled trial. World Journal of Orthodontics 2007; 8: 300-306.
9. Shawesh M, Bhatti B, Usmani T, Mandall N. Hawley retainers full or part time? A randomized clinical trial. Eur J Orthod 2010; 32: 165-170.
10. Thickett E, Power S. A randomized clinical trial of thermo-plastic retainer wear. Eur J Orthod 2010; 32: 1-5.
11. Hichens L, Rowland H, Williams A, et al. Cost-effectiveness and patient satisfaction: Hawley and vacuum-formed retainers. Eur J Orthod 2007; 29: 372-8.
12. Rowland H, Hichens L, Williams A, et al. The effectiveness of Hawley and vacuum- formed retainers: A single-center randomized controlled trial. Am J Orthod Dentofac Orthop

- 2007; 132: 730–7.
13. Proffit WR, Fields HW, Ackerman JL, Bailey LJ, Tulloch JF. Contemporary Orthodontics. 3rd ed. St. Louis: Mosby; 2000.
  14. Paudel S, Shrestha RM, Napit S. A century of Hawley retainer. *Orthod J Nepal*. 2021; 11(2):80-7.
  15. Needham R, Waring DT, Smith J, Malik OH. The invisible Hawley retainer. *Journal of orthodontics* 2015; 42(4):333-41.
  16. Al-Suliaman S, Hashim HA, Cordovez JL. The reinforced removable retainer. *J Contemp Dent Pract* 2006; 7(2):145-52.
  17. Sahoo KC, Pattanaik S. Modified wrap-around retainer: A quick tip to enhance the retention of the appliance. *Journal of Clinical and Diagnostic Research: JCDR* 2016; 10(7): ZH01.
  18. Korath AK, Jude C, Hattarki R. A Simple Screw-Type Wrap-Around Retainer. *J Indian Orthod Soc* 2022; 56(1):84-7.
  19. Graber TM. Orthodontics: Principles and Practice. 3rd ed.
  20. Raja TA, Littlewood SJ, Munyombwe T, Bubb NL. Wear resistance of four types of vacuum-formed retainer materials: a laboratory study. *Angle Orthod* 2014; 84(4):656-64.
  21. Millett DT, McDermott P, Field D, et al. Dental and Periodontal Health with Bonded or Vacuum-formed Retainer. In: IADR Conference Abstract 3168. Toronto, 2008.
  22. Abudiak H, Shelton A, Spencer RJ, Burns L, Littlewood SJ. A complication with orthodontic fixed retainers: A case report. *Ortho Update* 2011; 4: 112–117.
  23. Kucera J, Marek I. Unexpected complications associated with mandibular fixed retainers: A retrospective study. *Am J Orthod Dentofacial Orthop* 2016; 149: 202–11.
  24. Shaughnessy TG, Proffit WR, Samara SA. Inadvertent tooth movement with fixed lingual retainers. *Am J Orthod Dentofacial Orthop* 2016; 149: 277–86.
  25. Anjli P, Sandler J. First Aid for Orthodontic Retainers. *Dent Update* 2010;37:627–630..
  26. Patel A, Farhad, B, et al. Bonded Orthodontic Retainers. *Ortho Update* 2013;6:70–77.
  27. Artun J, Zachrisson B. Improving the handling properties of a composite resin for direct bonding. *Am J Orthod* 1982;81:269–276.
  28. Artun J, Spadafora AT, et al. A 3-year follow-up of various types of orthodontic canine-to-canine retainers. *Eur J Orthod* 1997;19: 501–509.
  29. White LW. The combination retainer. *Orthod Pract* 2011;2(2):72–73.
  30. Taner T, Haydar B, et al. Short-term effects of fiberotomy on relapse of anterior crowding. *Am J Orthod Dentofacial Orthop* 2000;118: 617–623.
  31. Doğramacı EJ, Jones VS, Jones AG. The Hawlix: a simple and aesthetic prosthetic-orthodontic retainer. *Aust Orthod J* 2016; 32(2):229-32.