

## PROCEDURAL ERRORS AND ENDODONTIC MISHAPS DURING ROOT CANAL TREATMENT: A REVIEW

Chahat Bansal<sup>1</sup>, Sunil Malhan<sup>2</sup>, Arvind Arora<sup>3</sup>, Gursandeep Kaur<sup>4</sup>, Himanshu Sood<sup>5</sup>

PG student<sup>1</sup>, HOD<sup>2</sup>, Professor<sup>3</sup>, Reader<sup>4</sup>, Senior Lecturer<sup>5</sup>

Department of Conservative Dentistry & Endodontics, Desh Bhagat Dental College & Hospital, Mandi Gobindgarh, India

### Abstract

Procedural errors in endodontics, or alternatively, any mistake that occurs at some point in the process of root canal treatment of a tooth can be a result of factors which the operator has both control, as well, no control over. For the majority of these mistakes the operator is at fault, either through lack of operator knowledge or concentration during treatment. This is fortunate in the sense that this means these errors are, in the main, preventable. Keeping in mind that dentists, being human, will commit errors at some point in their career, knowledge as to how to manage these situations is indispensable. As there exists a multitude of possible procedural errors, the areas that are going to be focused on are those which occur more commonly, and those with more disastrous sequelae.

**Keywords:** Endodontic mishaps, Root canal treatment,

### Introduction

Endodontic mishaps or procedural accidents are those unfortunate occurrences that happen during treatment, some owing to inattention to detail, others totally unpredictable. Recognition of a mishap is the first step in its management; it may be by radiographic or clinical observation or as a result of a patient complaint. Correction of a mishap may be accomplished in one of several ways depending on the type and extent of procedural accident. Re-evaluation of the prognosis of a tooth involved in an endodontic mishap is necessary and important. The re-evaluation may affect the entire treatment plan and may involve dentolegal consequences.<sup>1</sup>

According to Ingle and Bakland<sup>1</sup> endodontic mishaps can be access related which are due to treating the wrong tooth, missed canals, damage to existing restoration, access cavity perforations, crown fractures; Instrumentation related which are due to ledge formation, perforations, separated instruments and foreign objects, canal blockage; Obturation related due to over/under-extended root canal fillings, nerve paresthesia, vertical root fractures and other forms such as post space perforation and irrigant related<sup>2</sup>. The fact that these mistakes are preventable is fortunate since, as the old age "prevention is better than cure" states, it is preferable to having to manage the situation<sup>3</sup>.

### Classification:

According to Ingle (5th Edition):

#### a) Access Related:

- Treating the wrong tooth
- Missed canals
- Damage to existing restoration
- Access cavity perforations
- Crown fractures

#### b) Instrumentation Related:

- Ledge formation
- Cervical canal perforations
- Midroot perforations
- Apical perforations
- Separated instruments and foreign objects
- Canal blockage

#### c) Obturation Related:

- Over- or underextended root canal fillings
- Nerve paresthesia
- Vertical root fractures

#### d) Miscellaneous:

- Post space perforation
- Irrigant related
- Tissue emphysema
- Instrument aspiration and ingestion

### Access-Related Mishaps:

#### (a) Treating the Wrong Tooth:

If there is no question about diagnosis, treating the wrong tooth falls within the category of inattention on the part of the dentist. Obviously, misdiagnosis may happen and should not be

automatically considered an endodontic mishap. But if tooth #23 has been diagnosed with a necrotic pulp and the rubber dam is placed on tooth #24 and that tooth opened, that is a mishap.<sup>1</sup>

**Recognition:** In the first instance, the error was probably a misdiagnosis; in the second instance, a tooth adjacent to the one scheduled for treatment was inadvertently opened.<sup>1</sup>

Correction includes appropriate treatment of both teeth: the one incorrectly opened and the one with the original pulpal problem.<sup>1</sup>

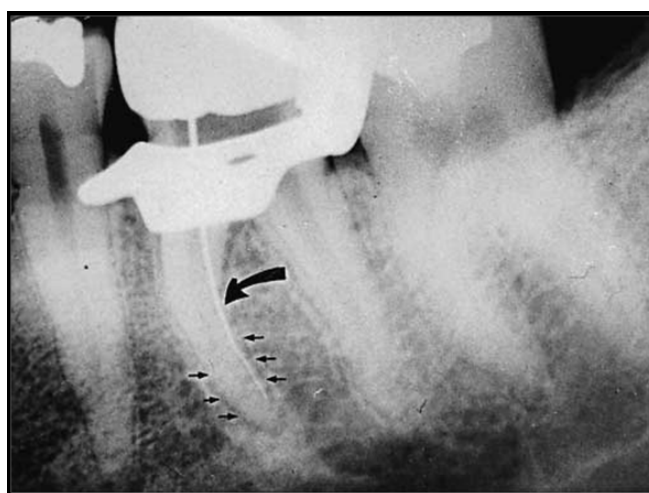
**Missed Canals:** Canals can be missed due to poor access and visibility of the canal orifice, lack of knowledge concerning tooth and pulpal anatomy and/or not thoroughly inspecting for extra canals; that is, having assumed that all the canals have

been located.<sup>3</sup>

**Etiology:** Lack of thorough knowledge of root canal anatomy along with its variations. Inadequate access cavity preparation.<sup>4</sup>

**Common Sites for Missed Canals:** Maxillary premolars may have three canals (mesiobuccal, distobuccal and palatal); Upper first molars usually have four canals; Mandibular incisors usually have extracanal; Mandibular premolars often have complex root anatomy; Mandibular molar may have extramesial and/or distal canal in some cases.<sup>4</sup>

**Correction:** Re-treatment is appropriate and should be attempted before recommending surgical correction.<sup>1</sup>



**Fig.1: Radiograph indicating the presence of a second, or missed, canal. By following the lamina dura of the root (small arrows), the eccentric position of the file (large arrow), with relation to the outline of the root, suggests the presence of a missed canal. In this case, a perforation is confirmed: the file is in the periodontal ligament, and the mesial canals have not been negotiated.**

#### **c) Damage to Existing Restoration:**

Extra-coronal restorations do not rule out root treatment or retreatment, but it should be noted that working through a crown is always more difficult, and that damage can be done.<sup>5</sup>

**Correction:** Minor porcelain chips can at times be repaired by bonding composite resin to the crown. However, the longevity of such repairs is unpredictable.<sup>1</sup>

#### **d) Access Cavity Perforations:**

They may occur during preparation of the access cavity, root canal space, or post space.<sup>1</sup>

**Causes:** Lack of attention to the degree of axial inclination of a tooth in relation to adjacent teeth and to alveolar bone may result in either gouging or perforation of the crown or the root at various levels.<sup>6</sup>

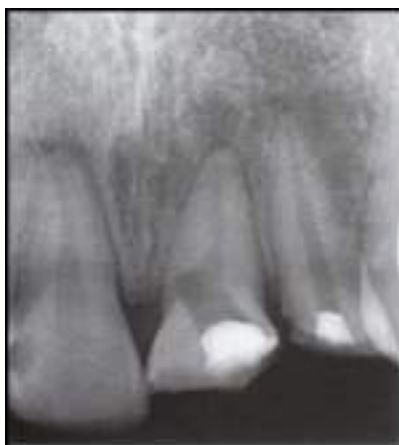**Recognition:** If the access cavity perforation is above the periodontal attachment, the first sign of the presence of an accidental perforation will often be the presence of leakage: either saliva into the cavity or sodium hypochlorite out into the mouth, at which time the patient will notice the unpleasant taste.<sup>7</sup> When the crown is perforated into the periodontal ligament, bleeding into the access cavity is often first indication of an accidental perforation.<sup>1</sup>

**Diagnosis:** Radiographs from multiple angles, including bitewing radiographs, will dramatically improve the clinician's diagnostic acuity.<sup>7</sup>

**Correction:** Several materials have been recommended for perforation repairs such as cavit, amalgam, calcium-hydroxide paste, super ethoxy-benzoic acid (EBA), glass-ionomer

cement, gutta-percha, tricalcium phosphate or hemostatic agents such as gelfoam and MTA

which has shown convincing results in apical cavity perforations.<sup>7</sup>



**Fig. 2: A misdirected bur created severe gouging and near-perforation during an otherwise routine access cavity preparation.**

#### **(e) Crown Fractures:**

The tooth may have a preexistent infraction that becomes a true fracture when the patient chews on the tooth weakened additionally by an access preparation<sup>1</sup>. Such fracture is usually recognized by direct observation.<sup>7</sup>

Recognition of such fractures is usually by direct observation. When infractions become true fractures, parts of the crown may be mobile.<sup>1</sup>

Treatment: Crown fractures usually have to be treated by extraction unless the fracture is of a “chisel type” in which only the cusp or part of the crown is involved; in such cases, the loose segment can be removed and treatment completed.<sup>7</sup>

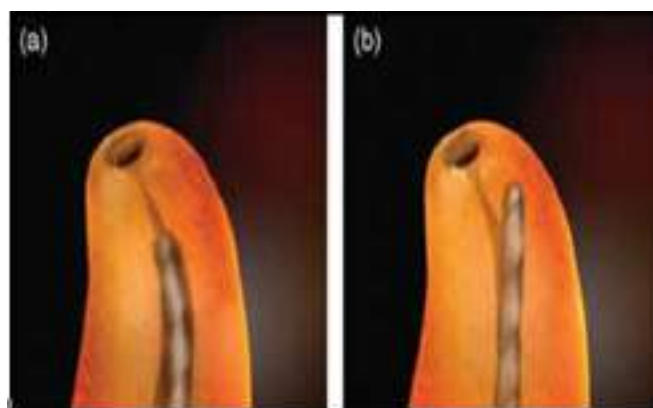
#### **Instrumentation Related:**

(a) Ledge formation:

Among the complications most commonly observed during root canal instrumentation is a deviation from the original canal curvature without communication with the periodontal ligament, resulting in a procedural error termed ledge formation or ledging.<sup>8</sup>

**Recognition:** There might be a loss of normal tactile sensation of the tip of the instrument binding in the lumen of the canal. This feeling is supplanted by that of the instrument point hitting against a solid wall, that is, a loose feeling with no tactile sensation of tensional binding.<sup>9</sup>

**Management:** When a ledge is suspected, root canal instrumentation should immediately cease, and efforts should be concentrated on regaining access to the apex using small-sized hand stainless-steel instruments.<sup>6</sup>



**Fig.3: (a) Ledge formed within the original canal path as a result of skipping instrument sizes or erroneous working length estimation. (b) False canal and a ledge as a result of misdirection of files.**

**(b) Canal transportation:**

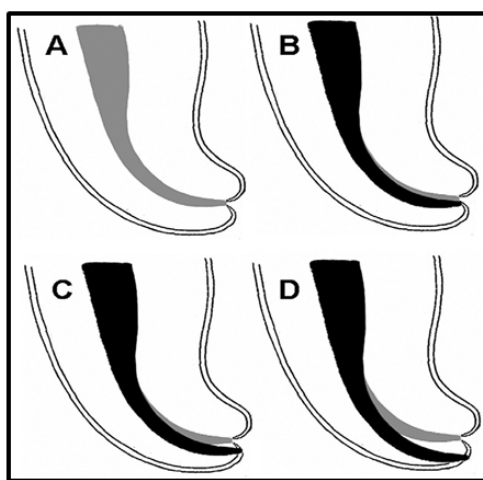
According to the Glossary of Endodontic Terms of the American Association of Endodontists, Canal transportation is defined as “Removal of canal wall structure on the outside curve in the apical half of the canal due to the tendency of files to restore themselves to their original linear shape during canal preparation; may lead to ledge formation and possible perforation.”<sup>10</sup>

**Etiology:** Insufficiently designed access cavities, inflexible canal preparation instruments, instrumentation technique like crown down preparation using hand instruments, degree and radius of a canal curvature.<sup>11</sup>

Recently a categorization of apical canal

transportation has been proposed:

- Type I: only a minor movement of the position of the physiological foramen, resulting in slight iatrogenic relocation.
- Type II: moderate movement of the physiological position of the foramen, resulting in a considerable iatrogenic relocation on the external root surface. In this type, a larger communication with the periapical space exists, and attempts to create a more coronal shape may weaken or perforate the root.
- Type III: severe movement of the physiological position of the canal, resulting in a significant iatrogenic relocation of the physiological foramen.<sup>12</sup>



**Fig.4: Types of canal transportation. (A) Regular canal shape; (B) Type I (minor movement of apical foramen; (C) Type II (moderate movement of apical foramen; (D) Type III transportation (severe movement of apical foramen).**

**Management:** Canals exhibiting Type I transportation may be cleaned and obturated conventionally, if sufficient residual dentin is maintained and a continuously tapered canal is created above the foramen. Type II cases are managed by placing a biocompatible barrier (e.g. MTA) to permit an obturation against them in order to avoid uncontrolled extrusion of root filling material from the root canal into the periapical tissues. In Type III situations, a barrier technique is usually not feasible; these canals require obturation as best as possible followed by corrective apical surgery.<sup>12</sup>

© **Perforations:** Perforation is an artificial opening between the root canal system and the surrounding tissues of teeth, which are either created by the clinician during entry into the root canal system and during cavity preparation or by a

biological event such as resorption or caries, resulting in communication between root canal and periodontal tissues.<sup>13</sup>

**Etiology:** Iatrogenic perforation occurs due to lack of knowledge about the internal anatomy of tooth structure and in the failure of analyzing possible variations in root canal system. Non-iatrogenic perforation occurs due to internal/external resorption, trauma, and caries involving the furcal area.<sup>13</sup>

Recognition often begins with the sudden appearance of blood, which comes from the periodontal ligament space. Rinsing and blotting (with a cotton pellet) may allow direct visualization of the perforation; magnification with either loupes, an endoscope, or a microscope is very useful in these situations.<sup>1</sup>

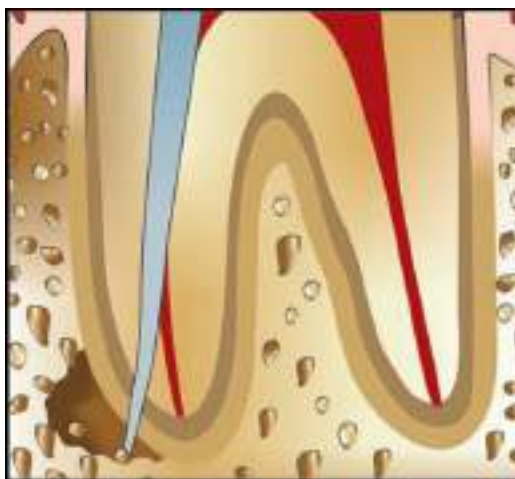
**Management:** The aim of perforation

management is regeneration of healthy periodontal tissues against the perforation without persistent inflammation or loss of periodontal attachment.<sup>14</sup> There are only two options in this case: repair or extraction.<sup>15</sup>

#### **Materials Used for Perforation Repair:**

Indium foil; Amalgam; Plaster of Paris; Zinc-Oxide Eugenol; Super EBA; IRM (Intermediate

Restorative Material); Gutta-Percha; Cavit; Glass-Ionomer Cement; Metal-Modified Glass-Ionomer Cement; Composite; Dentin chips; Decalcified Freezed Dried Bone; Calcium-Phosphate Cement; Tricalcium-Phosphate Cement; Hydroxyapatite; Calcium-hydroxide; Portland Cement; MTA; Biodentine; Endosequence; Bioaggregate; New Endodontic Cement.<sup>15</sup>



**Fig.5: Perforation caused by use of stiff instruments in a curved canal**

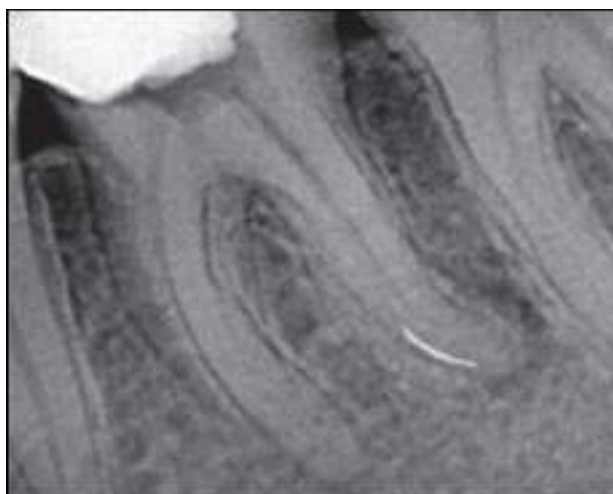#### **(a) Separated instruments and Foreign Objects:**

The term “broken instruments” applies not only to separated files, but it could also apply to a sectioned silver point, files, reamers, a segment of lentulo spiral, GG drill, lateral or finger spreaders. Limited flexibility and strength of intracanal instruments combined with improper use may result in an intracanal instrument separation.<sup>7</sup>

**Recognition:** Removal of a shortened file with a

blunt tip from a canal and subsequent loss of patency to the original length are the main clues for the presence of a separated instrument. A radiograph is essential for confirmation.<sup>6</sup>

**Management:** An immediate periapical radiograph is recommended so as to confirm the separation of the instrument, locate the instrument in the root canal, evaluate the anatomy of the root canal and measure the length of the fragment. The management of a separated instrument can be conservative and/or surgical.<sup>16</sup>



**Fig.6: Apical third fracture of an instrument.**



**(a) Canal Blockage:**

When a canal suddenly does not permit a working file to be advanced to the apical stop, a situation sometimes referred to as a “blockout” has occurred.<sup>1</sup>

**Etiology:** packed dentinal chips, tissue debris, cotton pellets, restorative materials or presence of fractured instruments,<sup>4</sup>

**Recognition:** When the confirmed working length is no longer attained canal blockage is recognized. Evaluation radiographically will demonstrate the file is not reaching near the apical terminus.<sup>7</sup>

**Correction:** is accomplished by means of recapitulation.<sup>1</sup> Copious irrigation with sodium-hypochlorite and a chelating agent can assist in dissolving tissue remnants and dentinal shavings blocking the root canal. Fine instruments (ISO

sizes 06 to 10) can be used to stir up the debris and to relocate the root canal up to its entire length.<sup>17</sup>

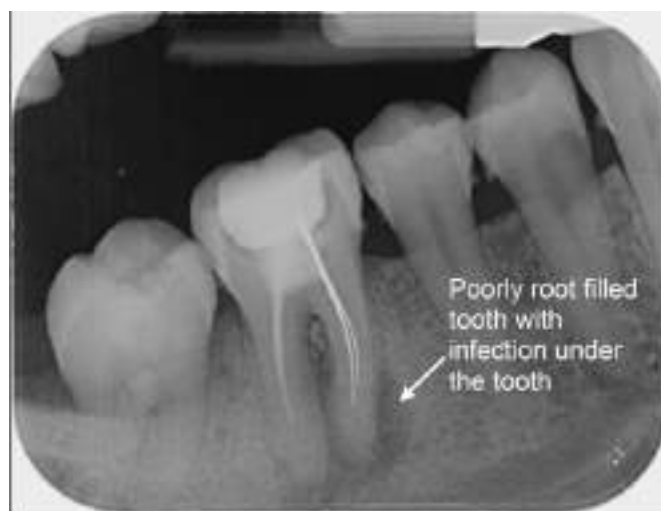**Obturation Related:**

(a) Over or under extended root canal fillings:

Traditionally, poor obturation has been considered the primary cause of root canal treatment failures.<sup>18</sup>

**Recognition:** of an inaccurately placed root canal filling usually takes place when a post-treatment radiograph is examined.<sup>1</sup>

**Correction:** An attempt to remove the overextension is sometimes successful if the entire point can be removed with one tug<sup>1</sup>. Periradicular surgery is indicated in case of significant overextension of filling material resulting in periradicular pathosis with symptoms.<sup>19</sup> Removal of underfilled gutta-percha and retreatment is preferred.<sup>6</sup>



**Fig.7: Underfilled root canals**

**(b) Nerve paresthesia:**

Paresthesia is defined as a burning or prickling sensation or partial numbness caused by neural injury. Patients have described it as warmth, cold, burning, aching, prickling, tingling, pins and needles, numbness and formication.<sup>20</sup> Overextensions or over instrumentations are the causative factors most often found in paresthesia secondary to orthograde endodontic therapy.<sup>1</sup>

**Diagnosis:** require a combination of a thorough anamnesis, a proper clinical evaluation, and an adjunct radiographic evaluation when indicated.<sup>21</sup>

**Management:** Early administration of anti-inflammatory drugs, such as corticosteroids or non-steroidal anti-inflammatory drugs may be

beneficial, even as a preventive approach in absence of a definitive diagnosis.<sup>21</sup>

**(c) Vertical root fractures:**

Vertical Root Fracture is defined as a longitudinal fracture confined to the root that usually begins on the internal canal wall and extends outward to the root surface. Diagnosis is challenging as signs and symptoms are often delayed.<sup>22</sup>

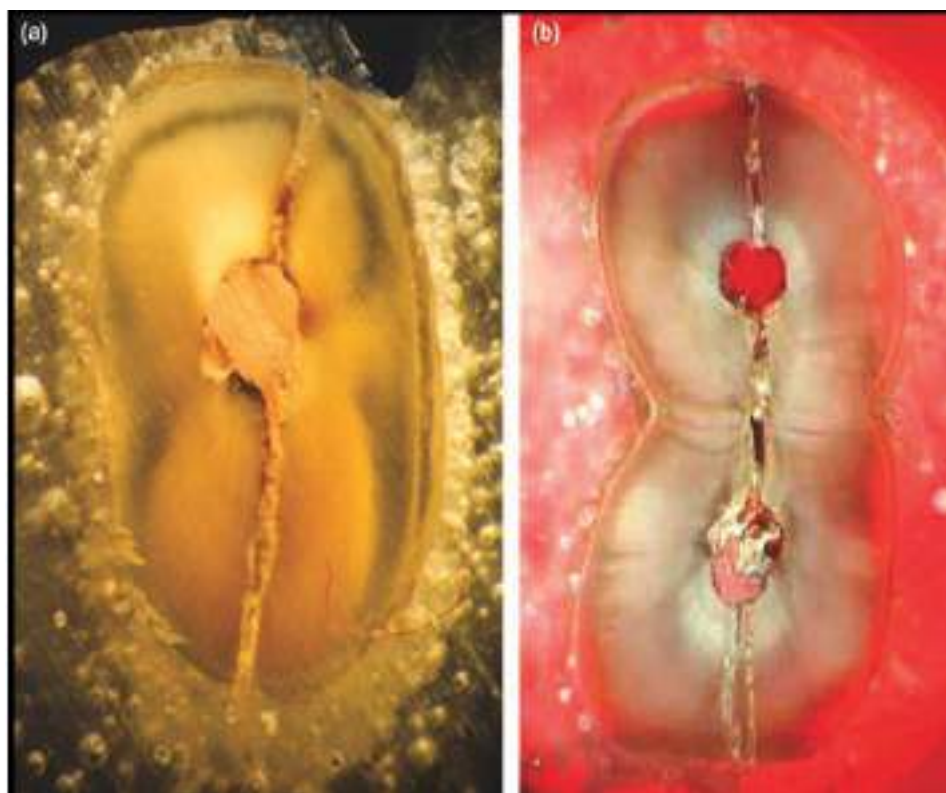
**Etiology:** Traumatic occlusion causes Fatigue Root Fracture. Gold inlays, large amalgam restoration undermining tooth structure, Excessive removal of tooth structure in endodontically treated teeth, Long term calcium-hydroxide as a root canal dressing may increase risk of root fracture.<sup>22</sup>

**Clinical diagnostic tests:** include Direct

visualization, Staining, Pulp testing, Bite test, Transillumination test, Periodontal probing test, Tracing the sinus tract.<sup>23</sup>

**Management:** When a diagnosis of vertical root fracture is made, a quick decision to extract the

tooth or root is necessary since, inflammation in the supporting tissues can lead to periodontal break-down, followed by development of a deep osseous defect and resorption of the bone.<sup>24</sup>



**Fig.8: Cross-section of a vertically fractured maxillary premolar showing a complete fracture from the buccal to the lingual aspect (A). (B) Complete fracture from the buccal to the lingual aspects of a maxillary premolar with two root canals is shown.**

### Miscellaneous

#### (a) Post space perforation:

Following obturation, careless post space preparation may result in perforation. Sometimes the post is not placed into the root canal but the adjacent dentine, resulting in catastrophic consequences.<sup>14</sup>

**Diagnosis:** If no local anaesthetic is given, sudden unexpected pain during treatment may also indicate a perforation. Apex locators, Operating microscopes, CBCT are becoming increasingly popular in identifying perforations.<sup>14</sup>

**Management:** Is surgical if the post cannot be removed. If the post can be removed, non-surgical repair is preferred.<sup>6</sup>

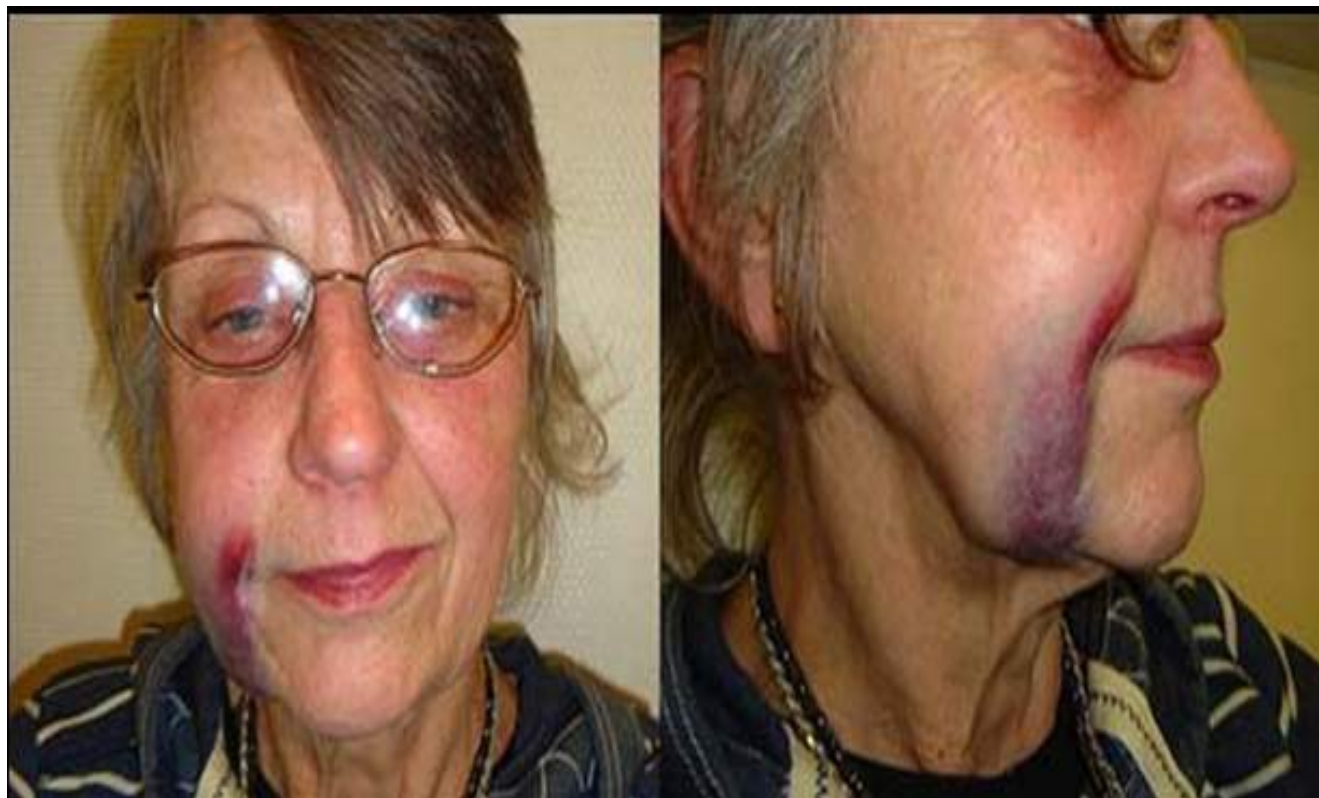(b) **Irrigant Related:** Efficacy of root canal irrigation depends on several factors, such as depth of needle insertion into the canal, final diameter of the prepared canal, canal curvature, volume and

properties of the used solution.<sup>25</sup> Hydrogen-peroxide, chlorhexidine, saline are some of the irrigants used; among which sodium-hypochlorite is the commonly used effective antimicrobial and tissue dissolving irrigant.<sup>26</sup> The most common complication is accidental injection into the periapical tissue. Injection of NaOCl solution beyond the apical foramen may occur in teeth with wide apical foramina or when the apical constriction has been destroyed during root canal preparation.<sup>27</sup>

#### Management of sodium hypochlorite accident:

- Stop treatment immediately and explain the situation to the patient.
- No further irrigation of the canal.
- Remove as much sodium-hypochlorite from tooth via an empty syringe to aspirate or use of paper points.
- Dress tooth with non-setting calcium hydroxide.

- Administer steroids (e.g. Intra-muscular 100 mg HYDROCORTISONE NA SUCCINATE) immediately.
- Oral antibiotics should be taken immediately and continued for 3 days. AMOXICILLIN 250mg TDS or METRONIDAZLE 200 mg TDS (in apenicillin allergic patient).
- Appropriate analgesia prescribed.<sup>28</sup>



**Fig.9:Significant right-sided facial swelling, bruising present explaining that a hypochlorite accident had occurred during root canal treatment**

#### **(c) Tissue emphysema:**

Subcutaneous emphysema (SCE) is defined as the abnormal presence of air under pressure, along or between fascial planes. The most common dental etiology of SCE is the introduction of air via the high-speed handpiece during restorative procedures or during the surgical resection of impacted teeth.<sup>29</sup>

**Clinical features:** Often seen is localized swelling, discomfort, and crepitus, with soft tissue radiographs or CT scans displaying tissue distension. Later sequelae are wide-spread edema, erythema, pyrexia, and sometimes pain.<sup>29</sup> Information of Subcutaneous

**Emphysema:** Broad-spectrum antibiotic coverage is advised in all dental-related cases, since the introduction of air may include microorganisms. In severe cases, immediate medical attention is mandatory. Tracheostomy

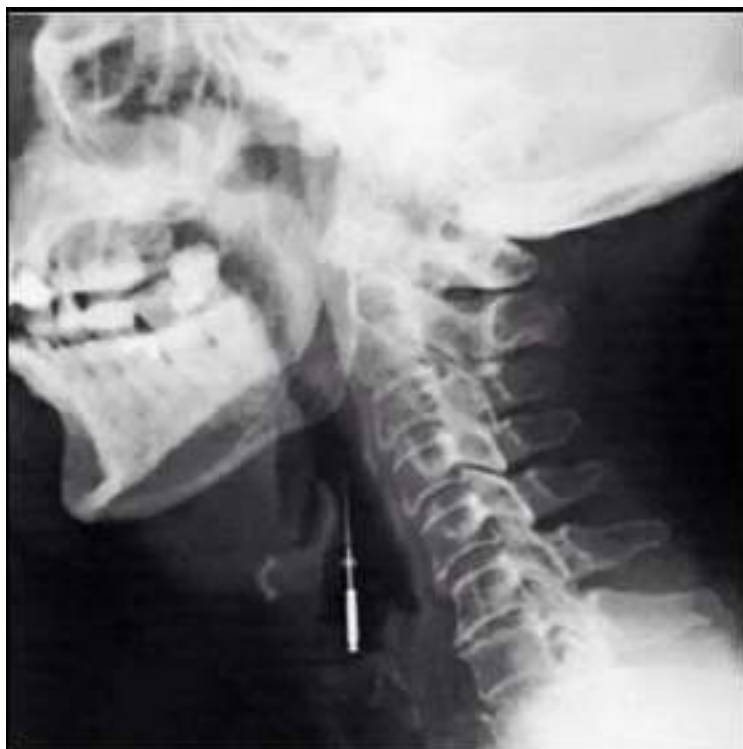may become necessary in case of retropharyngeal -space emphysema with consecutive airway compromise.<sup>30</sup>

#### **(d) Instrument Aspiration and Ingestion:**

Any object routinely placed into or removed from the oral cavity during dental or surgical procedures can be aspirated or swallowed. 31Aspiration of an endodontic instrument happens only when the rubber dam is not in place. Ingested objects of dental origin include dental bridges, transpalatal arch, crowns and removable dentures, dental floss, bands, impression materials, orthodontic arch wires, retention appliances and various endodontic instruments like broaches, files and reamers, restorations, restorative materials, instruments, implant parts, rubber-dam clamps, gauze packs.<sup>31</sup>

**Investigation methods:** Abdominal and Chest X-ray, Endoscopy, CT scans.<sup>32</sup>





**Fig.10: Root canal instrument into the trachea**

**Management: When any dental instrument is aspirated / swallowed:**

- Act quickly to locate and remove any object that may be causing acute upper airway obstruction.
- Keep the patient's head low, turn it to the side, and ask the patient to cough. Administer sharp blows on the patient's back.
- If object is visible, grasp it with small forceps, or use a suction tip, being careful not to push it deeper into the throat.
- If it is not possible to grasp the object, or if it is evident that the object is lodged in the airway (difficulty in breathing), the Heimlich manoeuvre may be attempted<sup>32</sup>.

**References**

1. Frank RJ. Endodontic Mishaps: Their detection, Correction and Prevention. In: Ingle Bakland, editor. Endodontics, 5th ed Harcourt Publishers 2003;769-794.
2. Mustafa M, Ustad F. A Note on Endodontic mishaps. American Journal of Advances in Medical Science.2015; 3(4),21-23.
3. Duigou C. Discuss the prevention and management of procedural errors during endodontic treatment. Aus End Jou 2004;30(2),74-77.
4. Garg N, Garg A. Procedural accidents. Textbook of Endodontics 3rd Edition 2014;364-385.
5. Madison S, Jordan R D, Krell K V. The effect of rubber dam retainers on porcelain fused-to-metal restorations. J Endod 1986;12,183-186.
6. Walton RE, Torabinejad M. Principles and practice of endodontics. 3rd ed. Philadelphia: W.B. Saunders Company; 2002,311.
7. Chaurasiya S, Yadav G, Tripathi AM, Dhinsa K. Endodontic Failures and its Management: A Review. Int J Oral Health Med Res 2016;2(5),144-148.
8. Jafarzadeh H. Ledge Formation: Review of a Great Challenge in Endodontics. J Endod 2007; 33,1155-1162.
9. Aravind N, Pradeep S. Management of ledge formation in root canal treatment. Int J Cur Adv Res 2017; 6 (4),3169-3171.
10. Chole D, Burad PA, Kundoor S, Bakle S, Devagirkar A, Deshpande R. Canal Transportation- A Threat in Endodontics: A Review. IOSR-JDMS 2016;15(7),64-72.
11. Weine F, Kelly R, Lio P. The effect of preparation procedures on original canal shape and on apical foramen shape. J Endod 1975;1,262-6.
12. Bürklein S, Schafer E. Critical evaluation of root canal transportation by instrumentation. Endodontic Topics 2013;29,110-124.
13. Senthilkumar V, Subbarao C. Management of root perforation: A review. J Adv Pharm Edu Res 2017;7(2),54-57.
14. Saed M, Ashley MP and Darcey J. Root perforations: aetiology, management strategies and outcomes. The hole truth. BDJ 2016; 220(4),171-180.
15. Kakani AK, Veeramachaneni C, Majeti C, Tummala M, Khiyani L. A review on perforation repair materials. Jou of Clin and Diag Res. 2015,9(9),09-13.
16. Vouzara T, Chares M, Lyroutdia K. Separated Instrument in Endodontics: Frequency, Treatment and Prognosis. Balk J Dent Med, 2018;123-132.
17. Hulsmann M. Prevention and management of problems during root canal treatment. ENDO (Lond Engl) 2016;10(3),127-140.

18. Yousuf W, Khan M, Mehdi H. Endodontic Procedural Errors: Frequency, Type of Error, and Most Frequently Treated Tooth. *IJD* 2015.
19. Pai ARV, Shrikrishna SB, Shah N. Surgical management of overfilled gutta-percha and root capping with MTA in a young patient. *Jou of Interdisciplinary Dent* 2014;4(3),148-151.
20. Mohammadi Z. Endodontics-Related Paresthesia of Mental and Inferior Alveolar Nerves: An Updated Review. *J Can Dent Assoc* 2010;76,117.
21. Rosen E. The diagnosis and management of nerve injury during endodontic treatment. *Rosen Evidence-Based Endodontics* 2017;2,7.
22. Abuwalla T, Goyal S, Choudhary S. Review of vertical root fractures in dentistry. *Ind Jou of Bas and App Med Res* 2016;5(3),791-797.
23. Dhawan A, Gupta S, Mittal R. Vertical root fractures: An update review. *J Res Dent* 2014;2,107-13.
24. Remya C, Indiresha HN, George JV, Dinesh K. "Vertical root fractures: A review," *Int J Contemp Dent Med Rev*, vol. 2015.
25. Tanomaru JMG, Loiola LE, Morgental RD, Leonardo RT, Filho MT. Efficacy of Four irrigation needles in cleaning apical third of root canals. *Brazilian Dental Journal* 2013;24(1),21-24.
26. Mathew ST. Risks and Management of Sodium Hypochlorite in Endodontics. *Oral Hyg Health* 2015;3(3),178.
27. Wang SH, Chung MP, Cheng JC, Chen CP, hieh YS. Sodium hypochlorite accidentally extruded beyond apical foramen. *J Med Sci* 2010;30(2),061-065.
28. Lavery DP. A case report of accidental extrusion of sodium hypochlorite into maxillary sinus during endodontic retreatment and review of current prevention and management. *J Res Dent* 2014;2,96-100.
29. Battrum DE, Gutmann JL. Implications, prevention, and management of subcutaneous emphysema during endodontic treatment. *Endod Dent Traumatol* 1995;11,109-114.
30. Liatiri S. Subcutaneous Emphysema after Root Canal Therapy. *Balk J Stom*, 2012;16,10-15.
31. Cameron SM, Whitlock WL, Tabor MS. Foreign body aspiration in dentistry: a review. *JADA* 1996;127(8),1224-1229.
32. Parolia A, Kamath M, Kundubala M, Manuel TS, Mohan M. Management of foreign body aspiration or ingestion in dentistry. *Kathm Uni Med Jou* 2009;7(26),165-171.